

Socket grafting and ridge preservation using Bond Apatite

Cases 1

Surgery Dr. David Baranes D.M.D

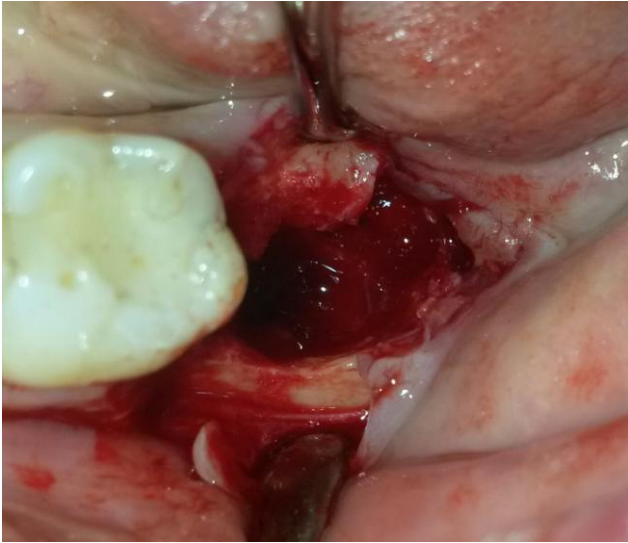Case 1 description

In this case the two inferiors hopeless molars 37 38 was removed .the socket and the ridge was preserve by augmenting the area with Bond apatite bone graft cement. After teeth removal and complete debridement of the site the application of the cement was according to the protocol in 3 consecutive steps ,**place ,press ,close** .

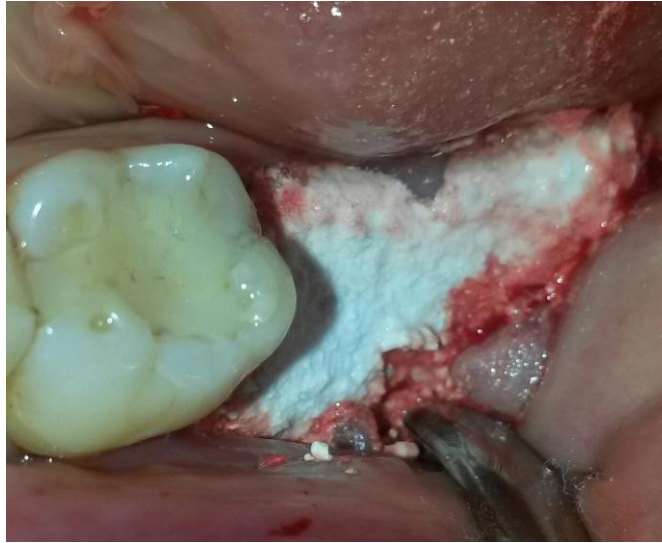the cement was ejected directly into the grafted site from its

”all in one ”syringe and then press firmly with a dry gauze for 3 second ,followed by primary soft tissue closure directly above the cement .no membrane was needed .

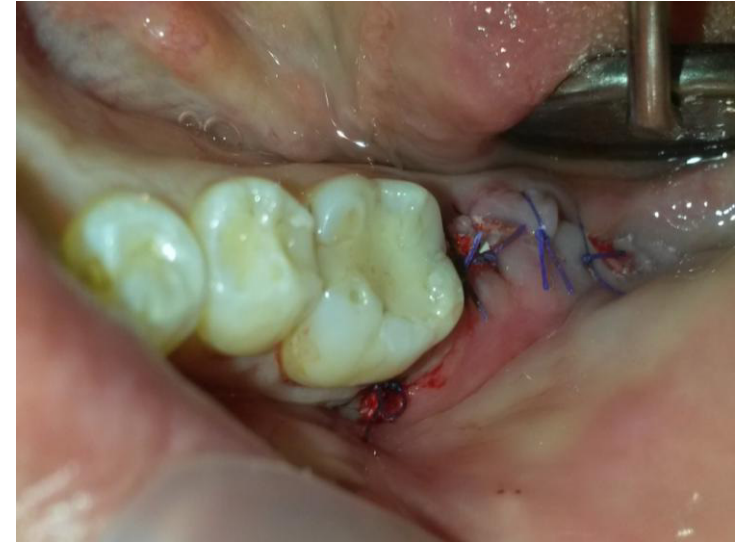12 weeks post op at reentry the new patient own bone was formed and the 3D ridge volume was preserved . At this stage implant placement took place



Large bone deficiency
after extraction of two hopeless molars.

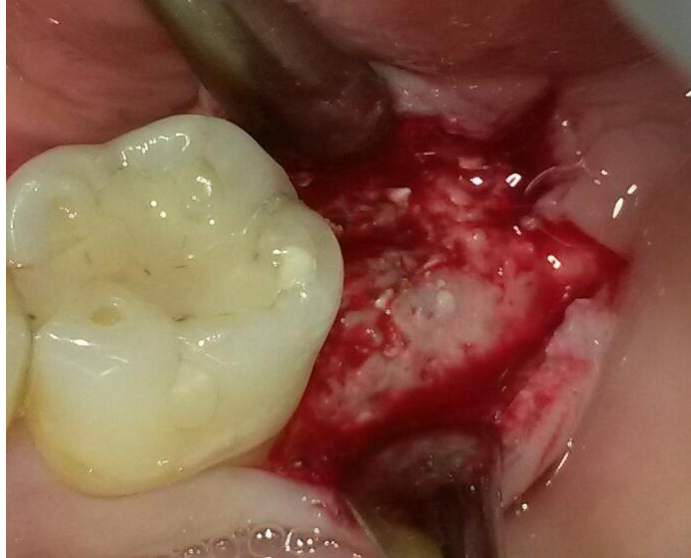

After site preparation,
Bond Apatite graft cement was
ejected into the site from its
"all-in-one syringe" by 3 simple
consecutive steps according to the
protocol.

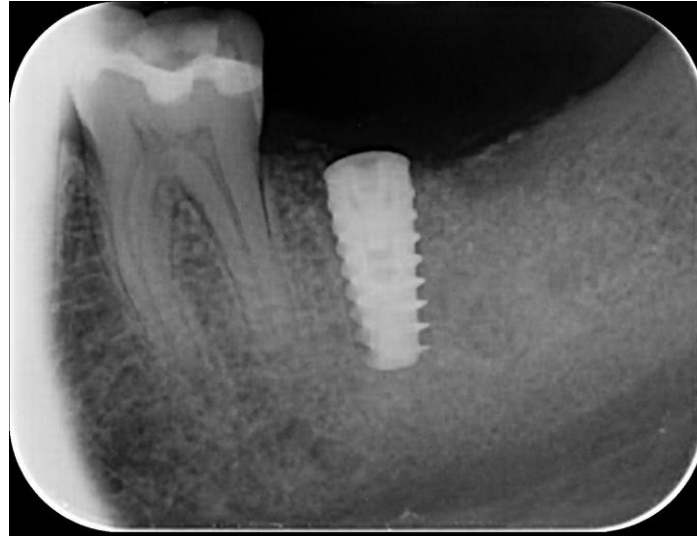


Soft tissue is primarily closed above the
graft without using a membrane.

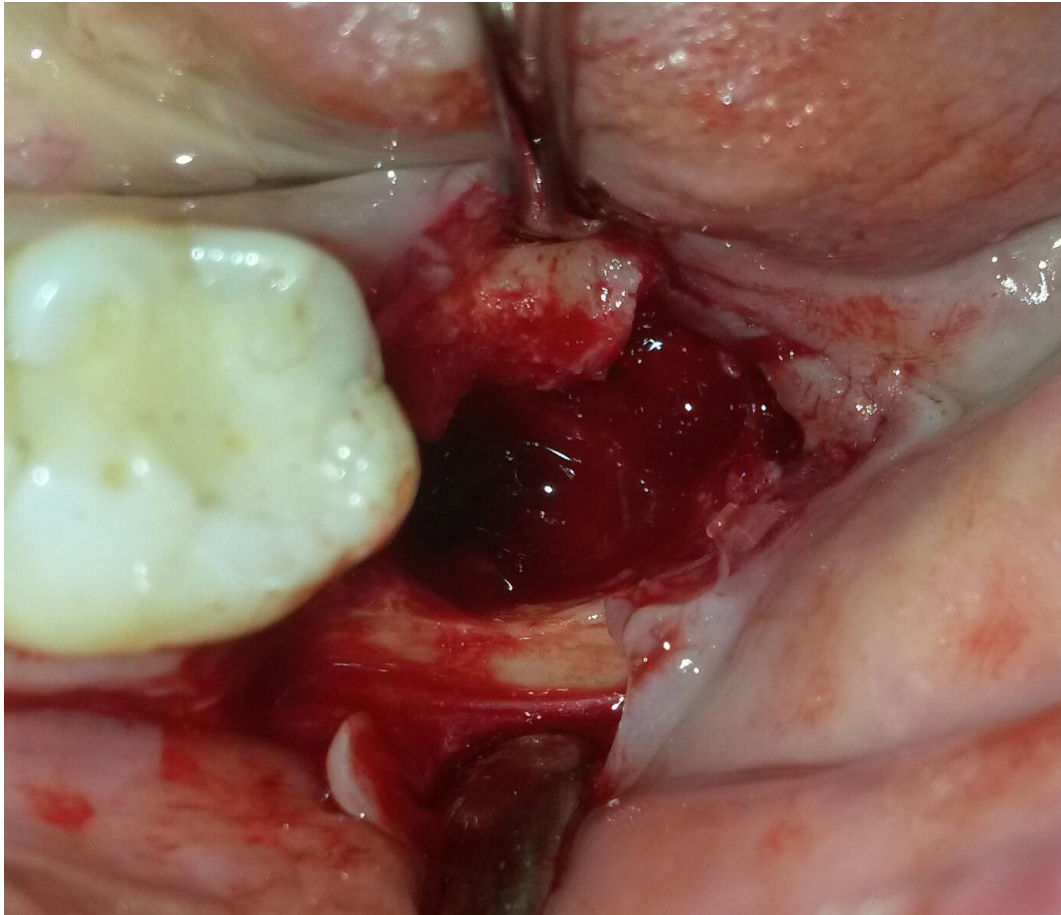
Surgery Dr. David Baranes D.M.D



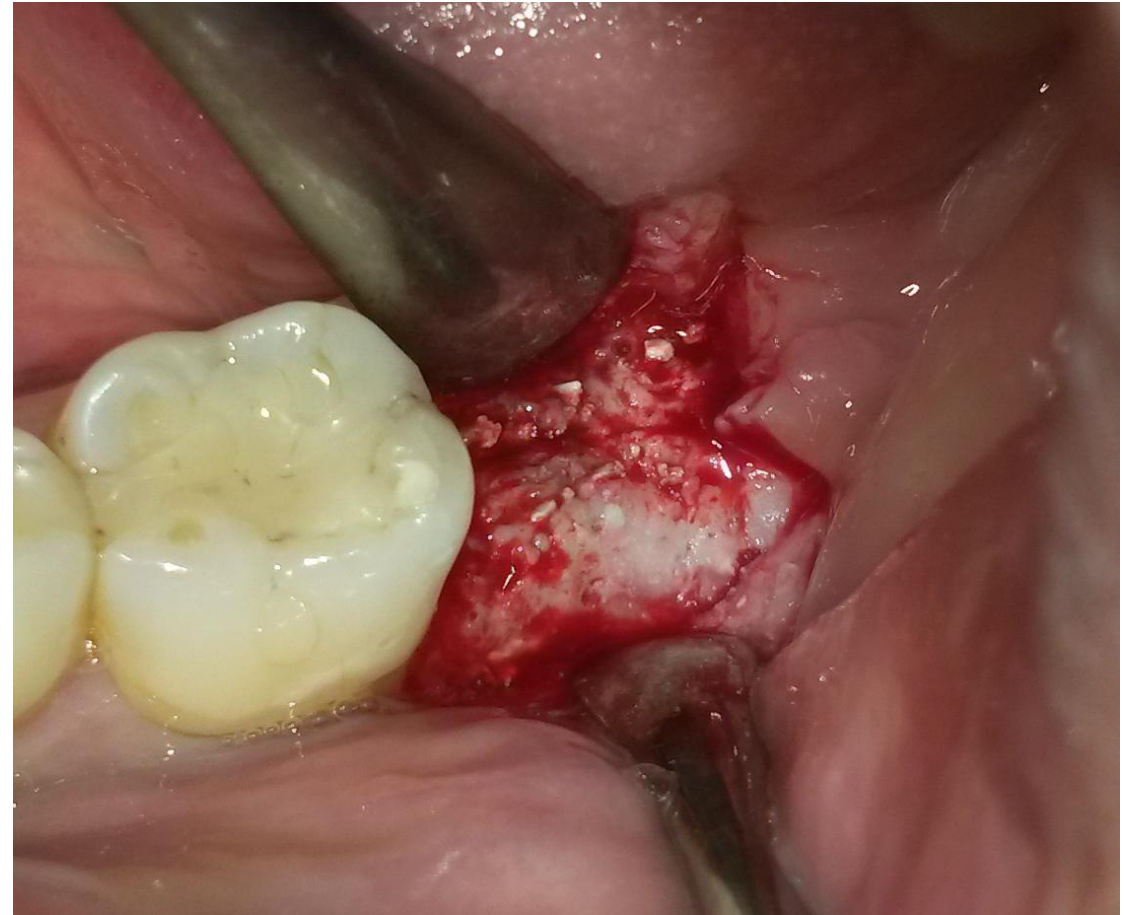Complete regeneration of the grafted site can be seen at the reentry stage 3 months post-op.



Periapical radiographic appearance of the Augmented site with the implant in place.



Before augmentation

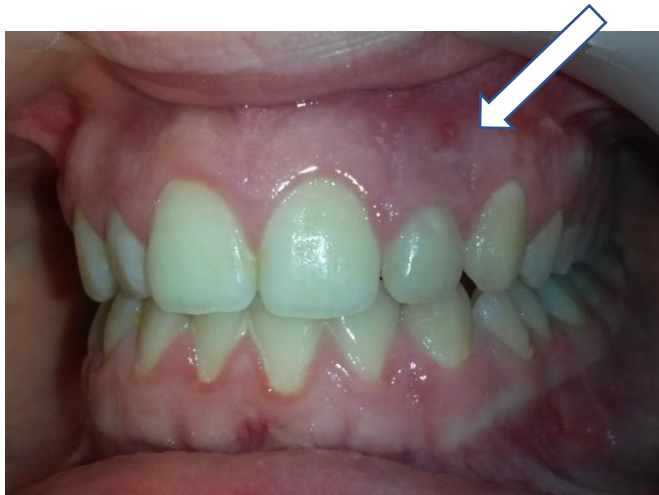

At reentry stage

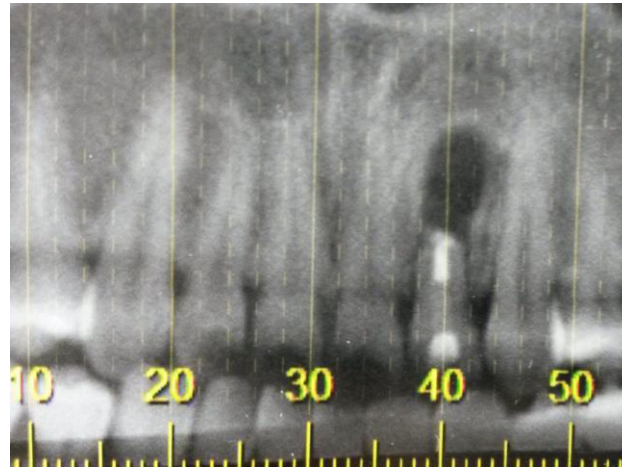
Surgery Dr. David Baranes D.M.D

Case 2

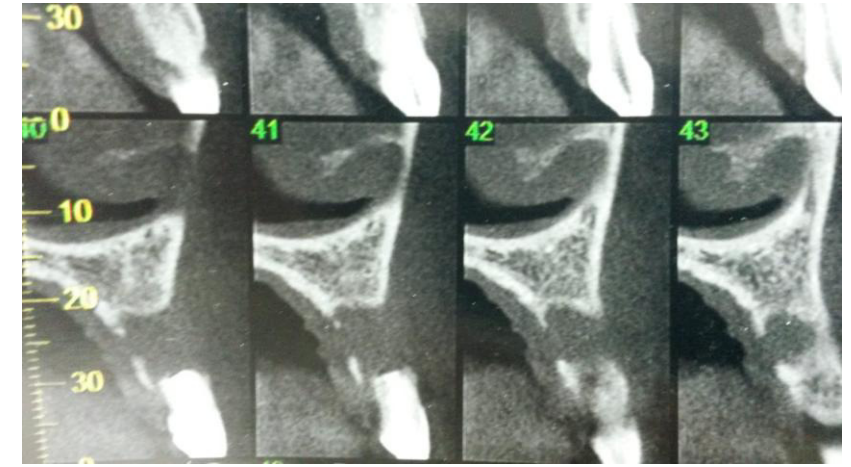
Bone reconstruction in the aesthetic zone



Fistula can be seen during Clinical examination



Periapical and CBCT scan slice radiographic appearance reveal large bone deficiency at the apical. Portion of the upper lateral incisor that was treated unsuccessfully by epecoectomy 4 years earlier.



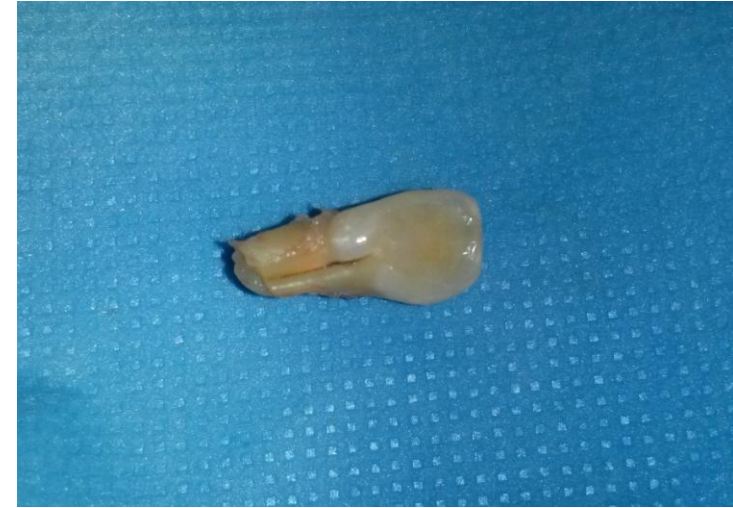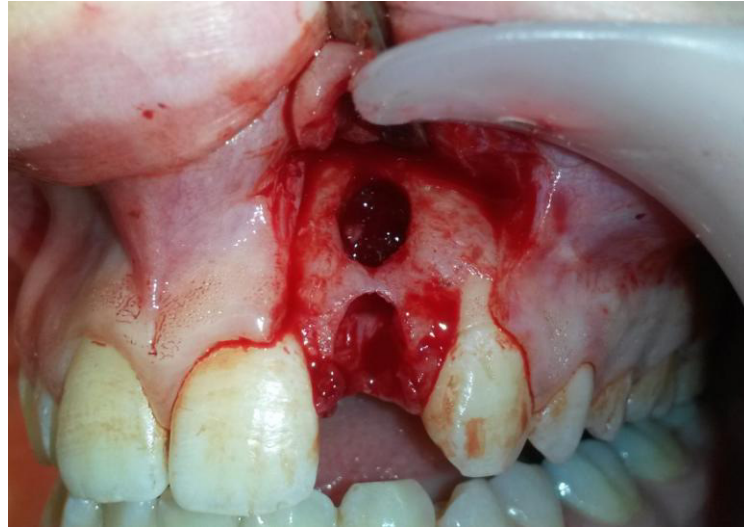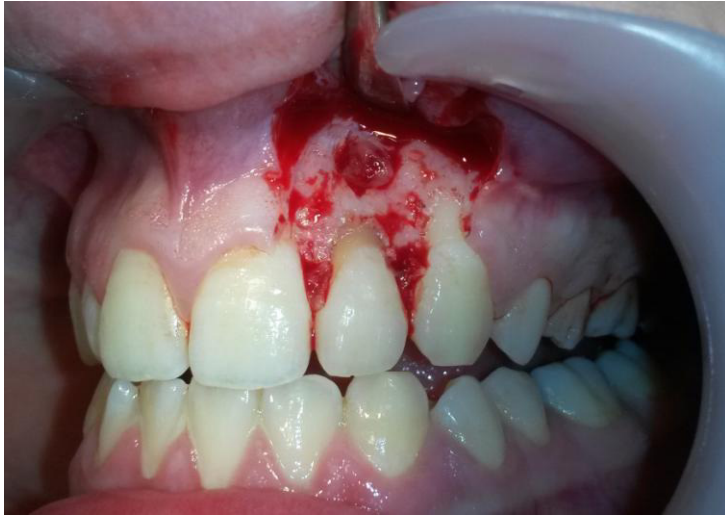Case 2 –case description

In the following case a 30 years old female came to the clinic describing discomfort feeling and tooth mobility of the left upper lateral incisor. During clinical evaluation a fistula was detected buccally near the apex zone of the tooth. Preapical radiographic evaluation revealed a large radiolucency in connection with the tooth apex.

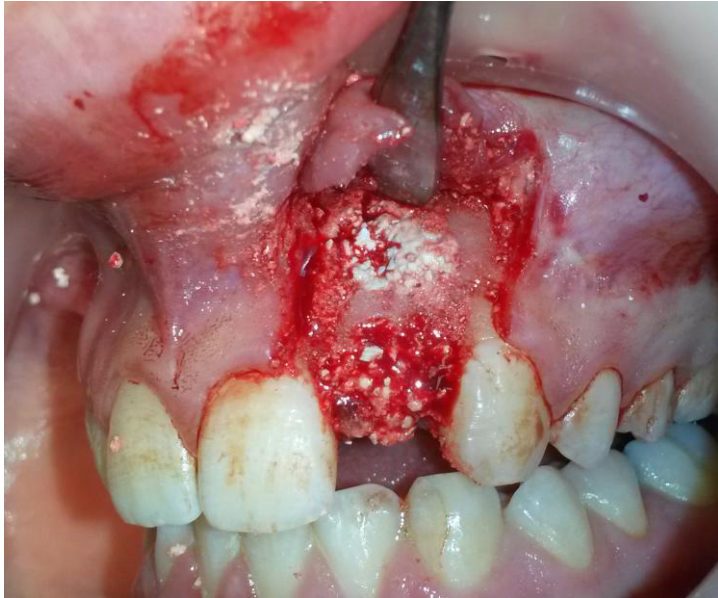The treatment plan was to extract the tooth and to remove the lesion. To augment and to place an implant at the second stage.

After the extraction and the site preparation for augmentation Bone Apatite cement was used as a graft material. The soft tissue was primarily closed directly above the graft without using any membrane.

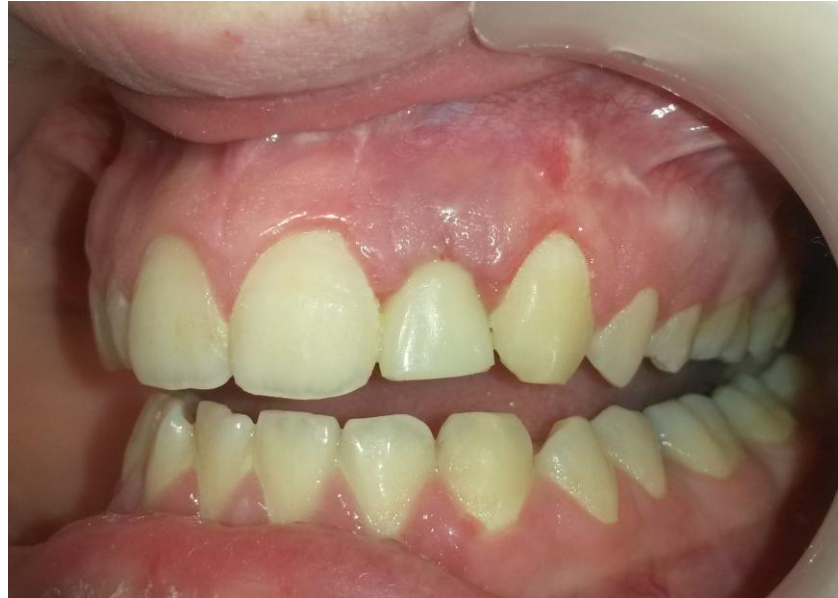3 months post op one piece implant was placed and loaded with provisional acrylic crown.



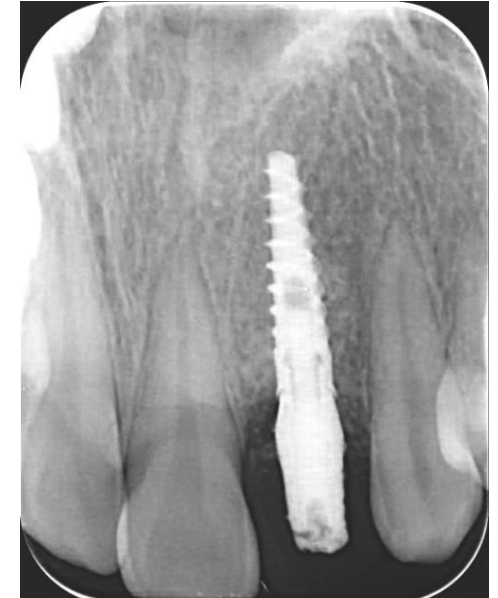The defected tooth was carefully extracted and the granulation soft tissue was removed completely .
Leaving behind a large bone defect with buccal plate deficiency.



Bond apatite was placed in the Augmented site.



3 months post-op at the second stage implant was placed with provisional acrylic crown.

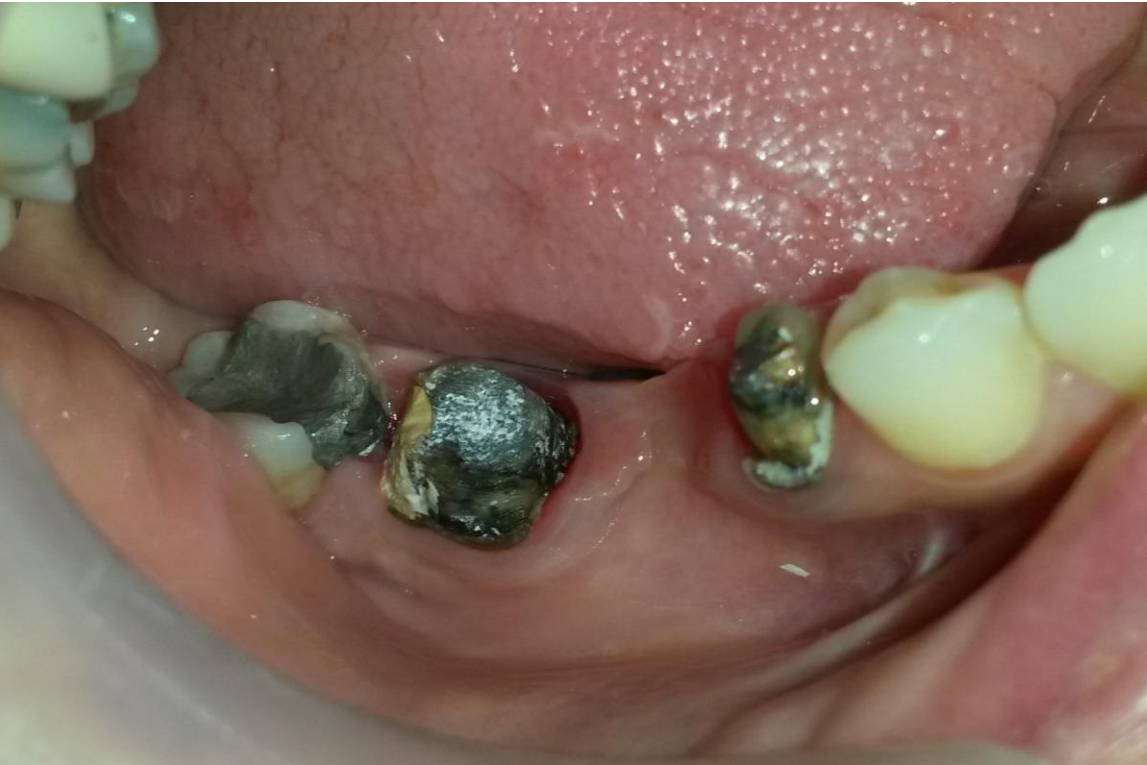

Radiographic appearance with implant in place.

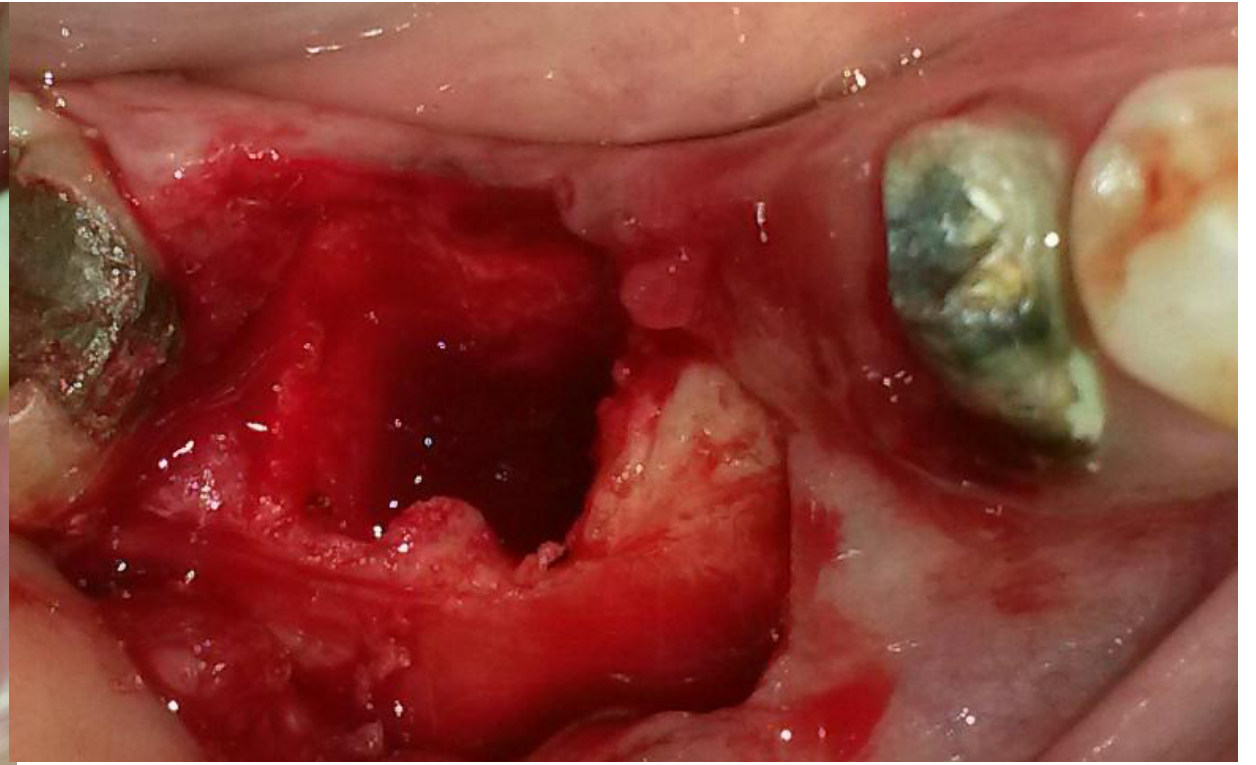
Surgery Dr. David Baranes D.M.D

Case 3

Extraction followed by immediate implant placement and augmentation using Bond Apatite.



Before second molar removal

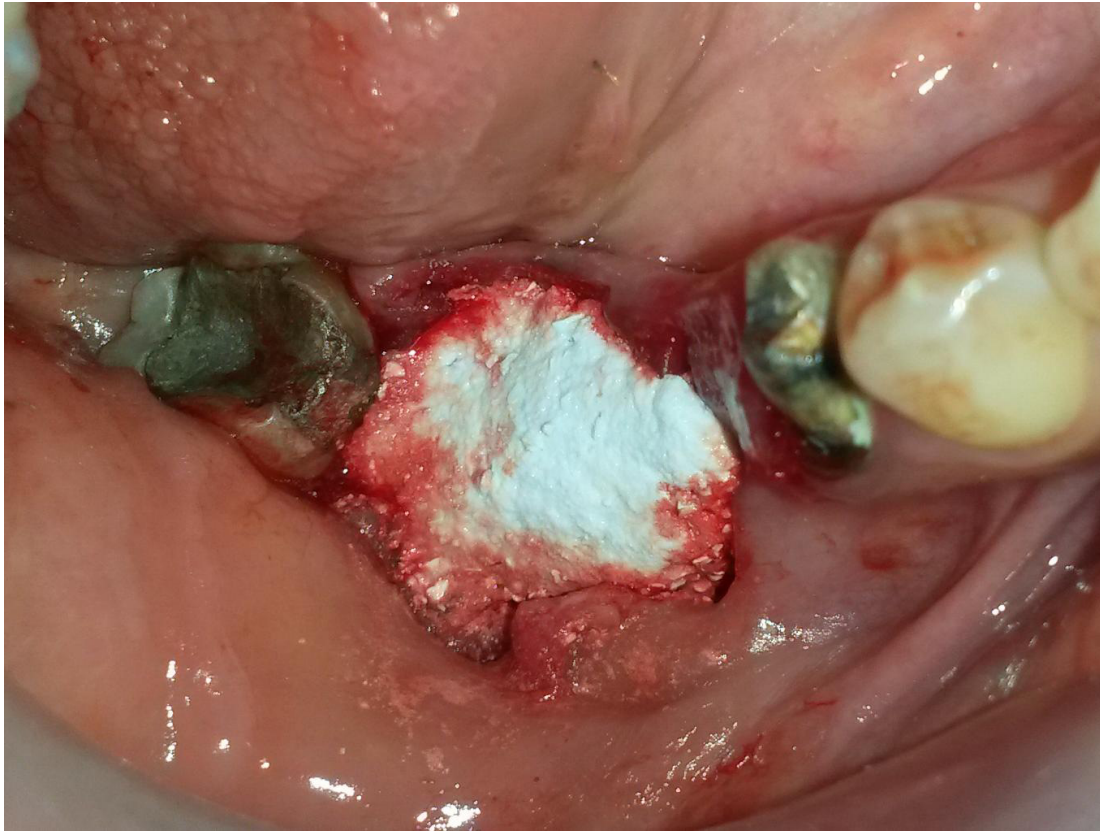


After extraction of the second molar.

Case 3 case description

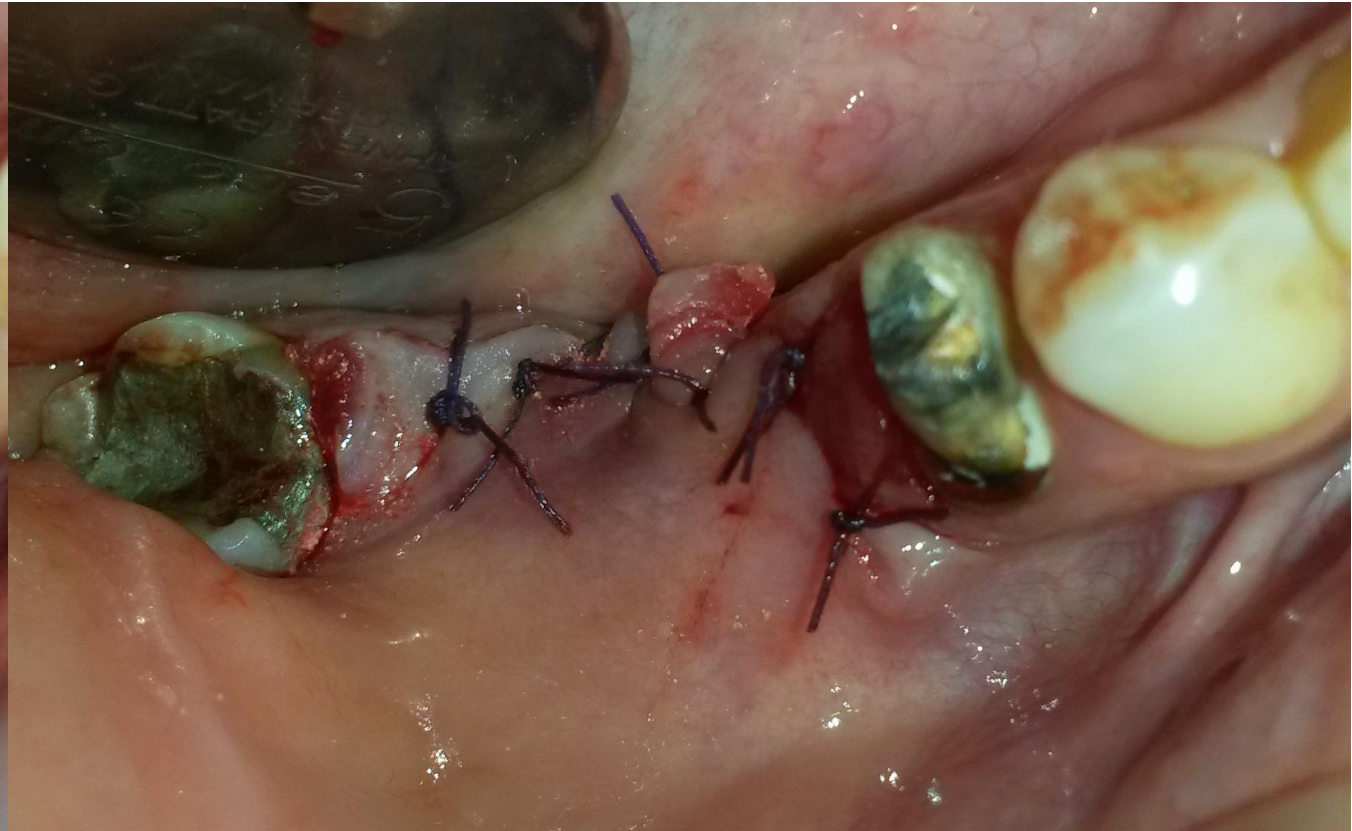
In this case in the right lower side first molar was missing and the second one sentenced to be extracted . Two implant were placed at the procedure time one in the first molar zone and the other in the extracted site .primary stability was tested and verified for both implants before the socket was augmented and preserved. As augmentation material Bond Apatite bone graft cement was choose .

After 3 months at the reentry the implant was well integrated .and a bur was use to uncover the healing screw from the overlaid bone.

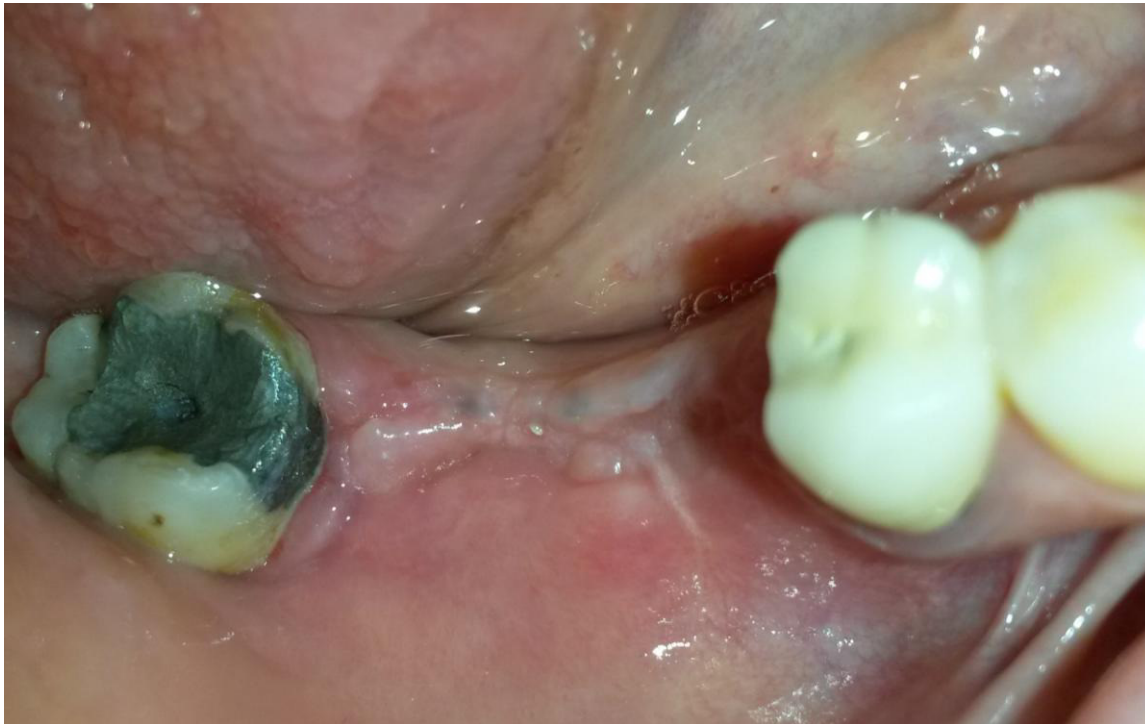

Augmentation with Bond Apatite cement was performed simultaneously with placement of the implant. In such cases, the implant should be anchored to the bone with good primary stability that comes from the bone and not from the cement.

Surgery Dr. David Baranes D.M.D

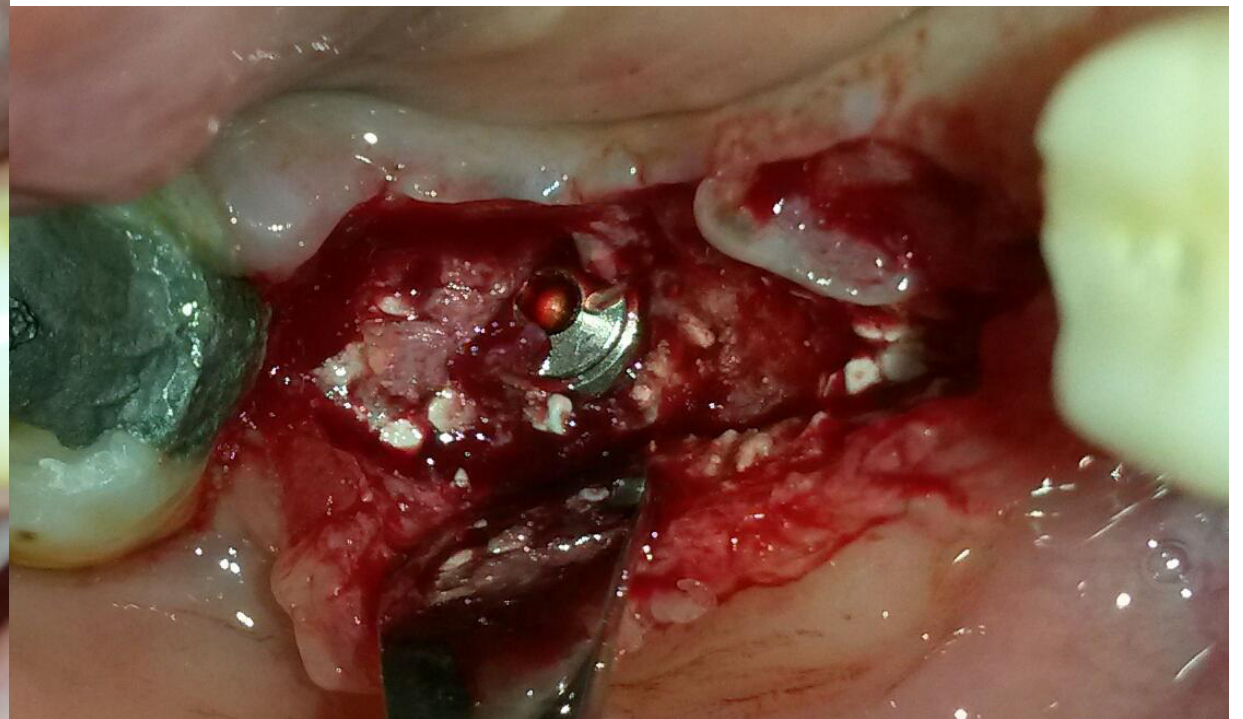


Membrane coverage is not required however the flap should be primary closed.

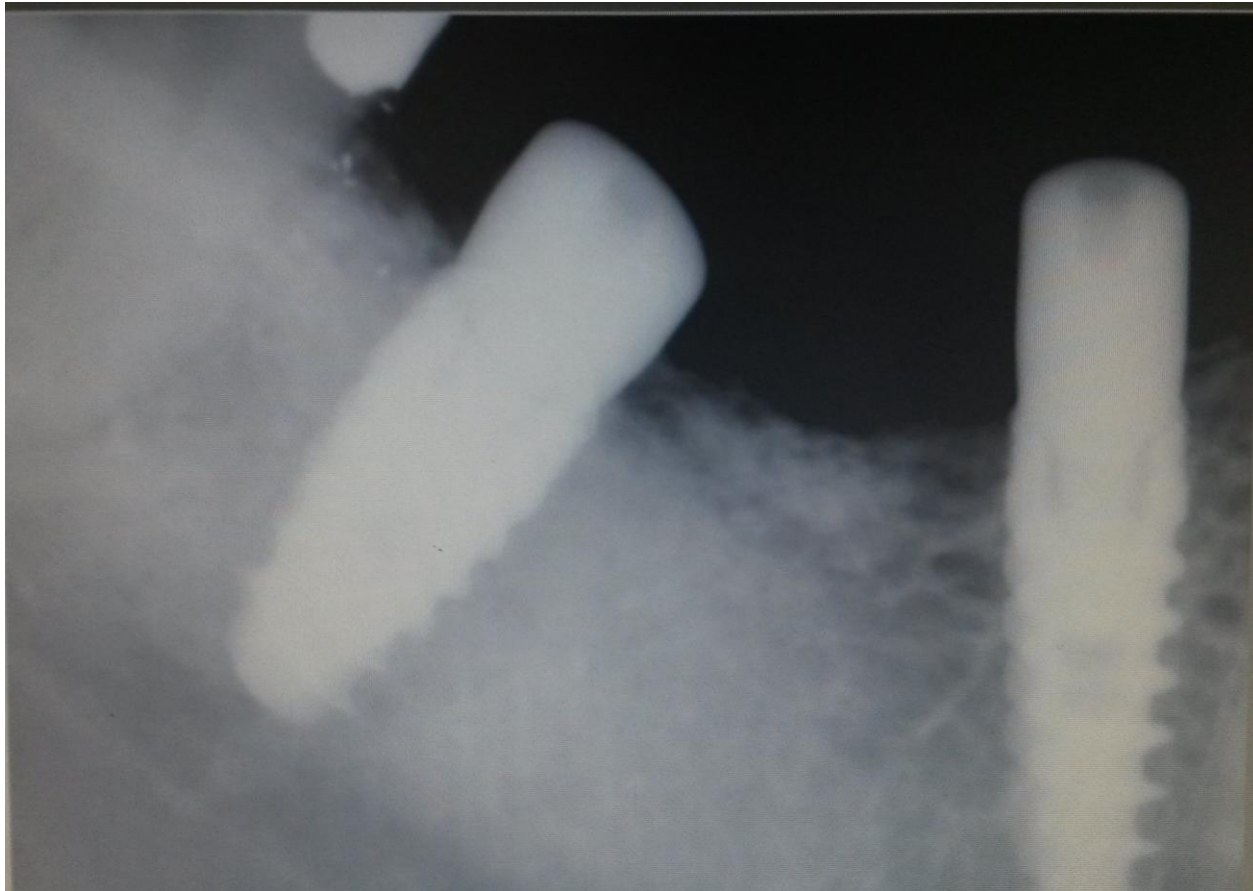

Soft tissue appearance 3 months post-op.

Surgery Dr. David Baranes D.M.D



During reentry the implant head was submerged under the new formed bone a bur was used to uncover the healing screw.

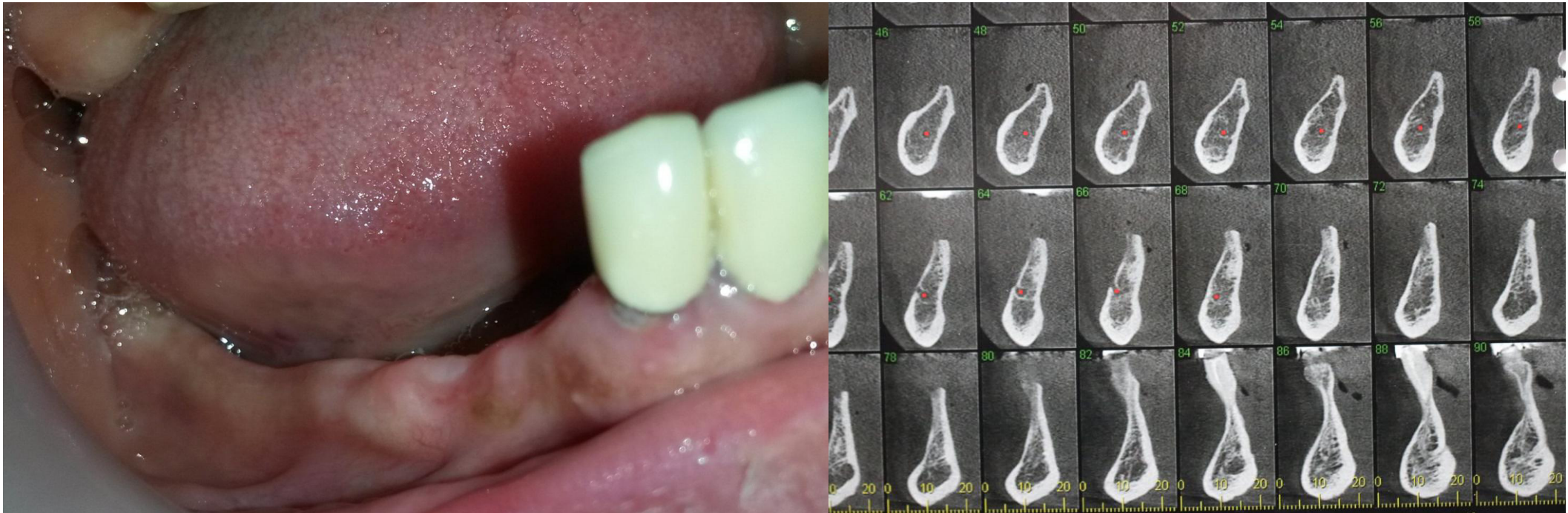


Radiographic appearance 3 months post op

Surgery Dr. David Baranes D.M.D

Case 4

Lateral augmentation and implant placement using Bond Apatite[®]



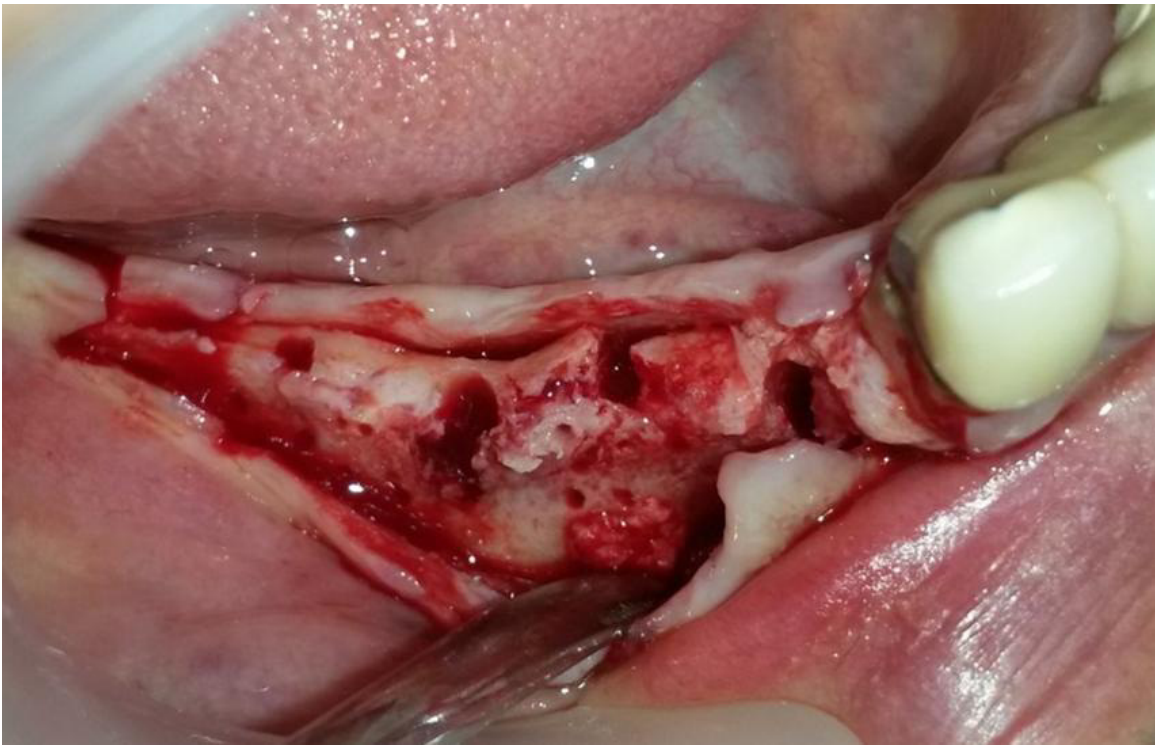Narrow ridge at the lower jaw clinical and radiographic appearance.

Case 4 case description

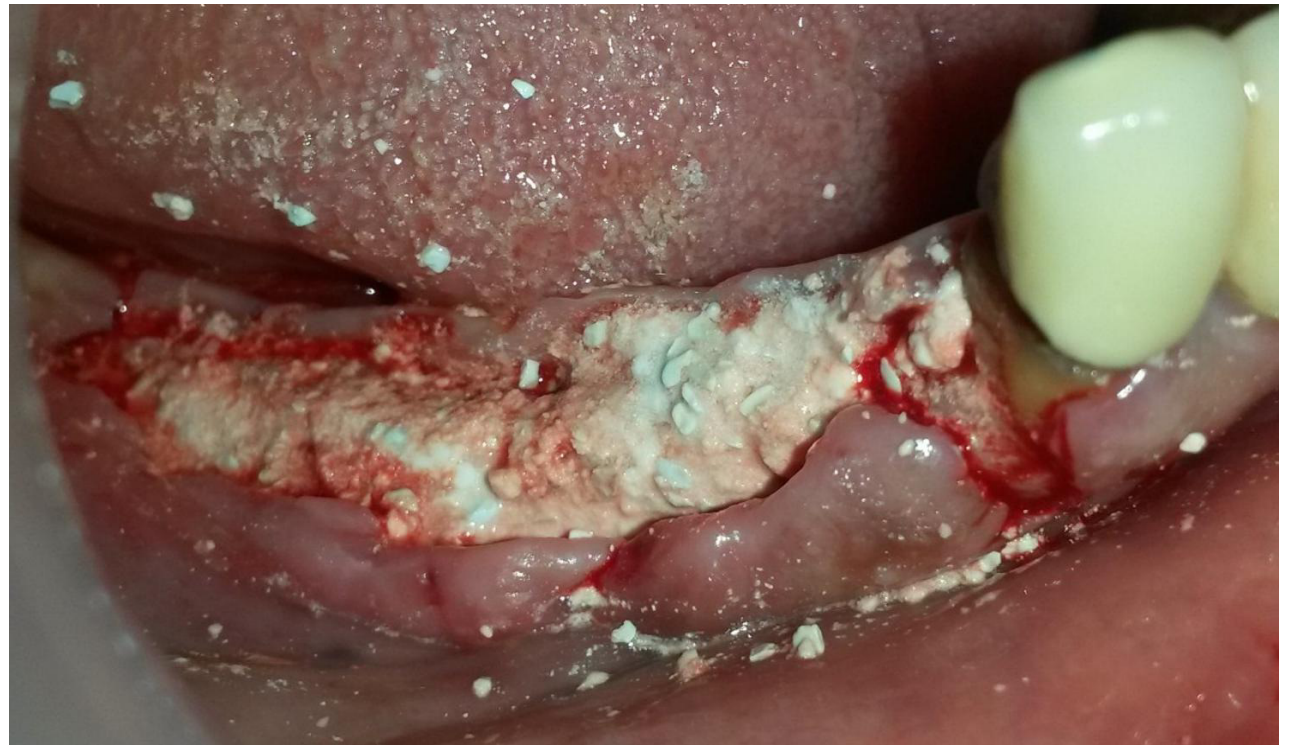
Lateral augmentation can be challenging .unless bone cements are used.

In this case a very narrow ridge was augmented simultaneously with implant placement. The ridge and the exposed implant threads was augmented and covered by Bond apatite Bone graft cement .

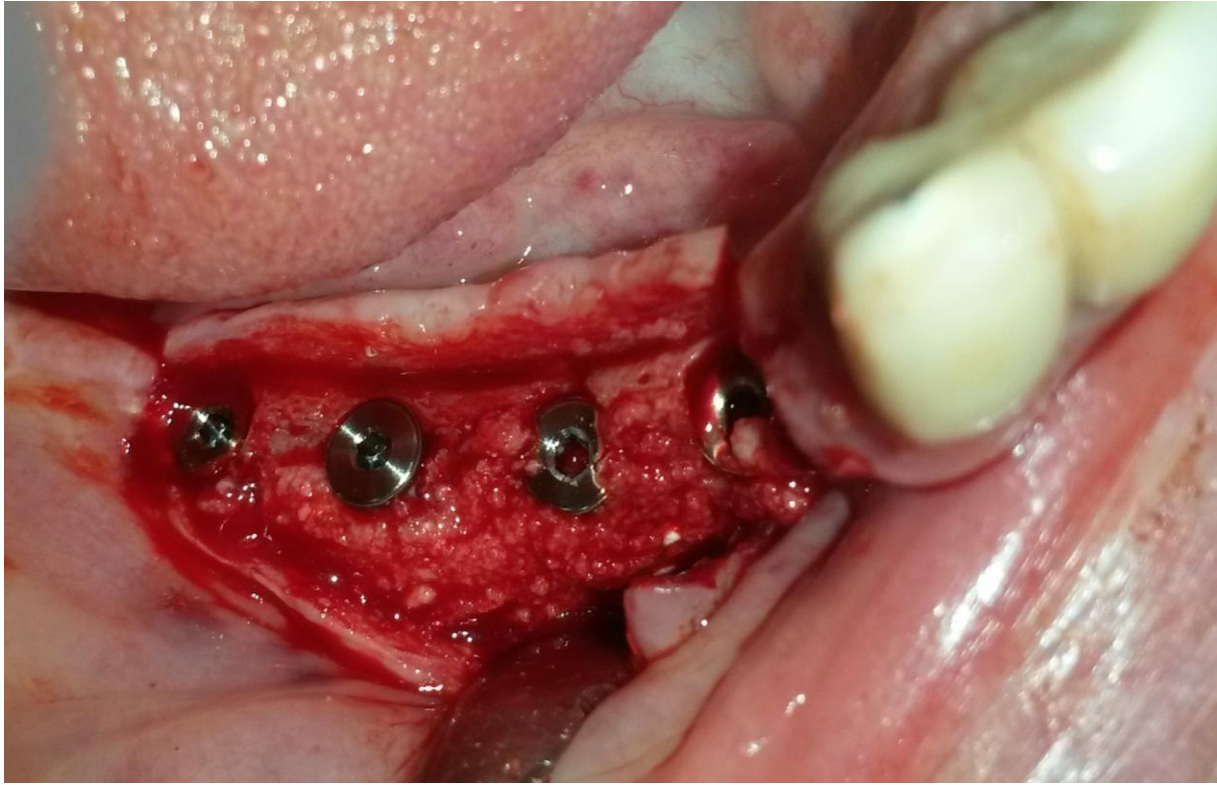
Due to the cement nature the application was very simple .after flap reflection, the site was prepared and the implant was placed ,soft tissue was slightly released(not need to be tension free as we are used to do when a membrane is use).the cement was ejected into the site and pressed firmly for 3 second with a dry gauze and then the site was closed immediately and directly above the graft . No membrane is required in such case ,the flap should be primary closed , and as opposite to cases when membrane is used here the flap should be with even a bit of tension to prevent its movement. However well sutured and primary closed (up to 2-3 mm exposure is not an issue).



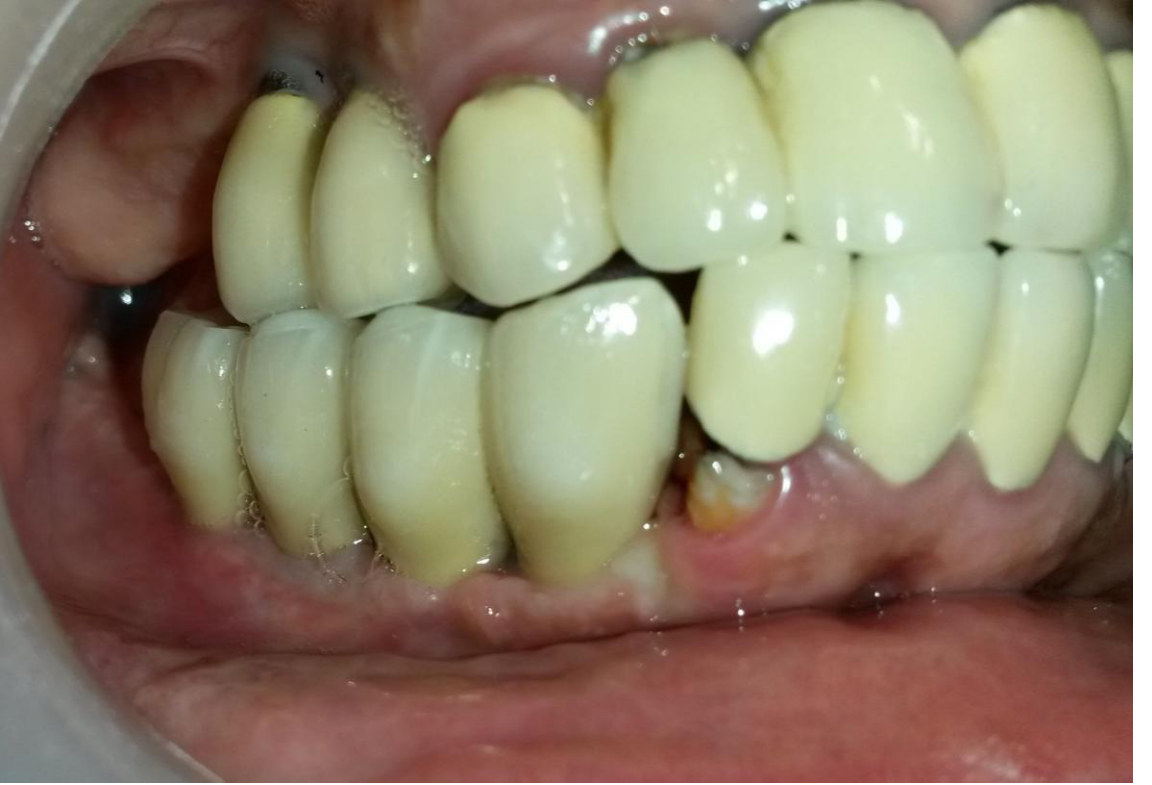Site preparation before implant placement.



After implant placement the entire area was grafted by using Bond Apatite® cement.



4 months post op at reentry the implants was well integrated surrounded by adequate bone width.



Final prosthetic in place.